

EAES Consensus Development Conference on endoscopic repair of groin hernias

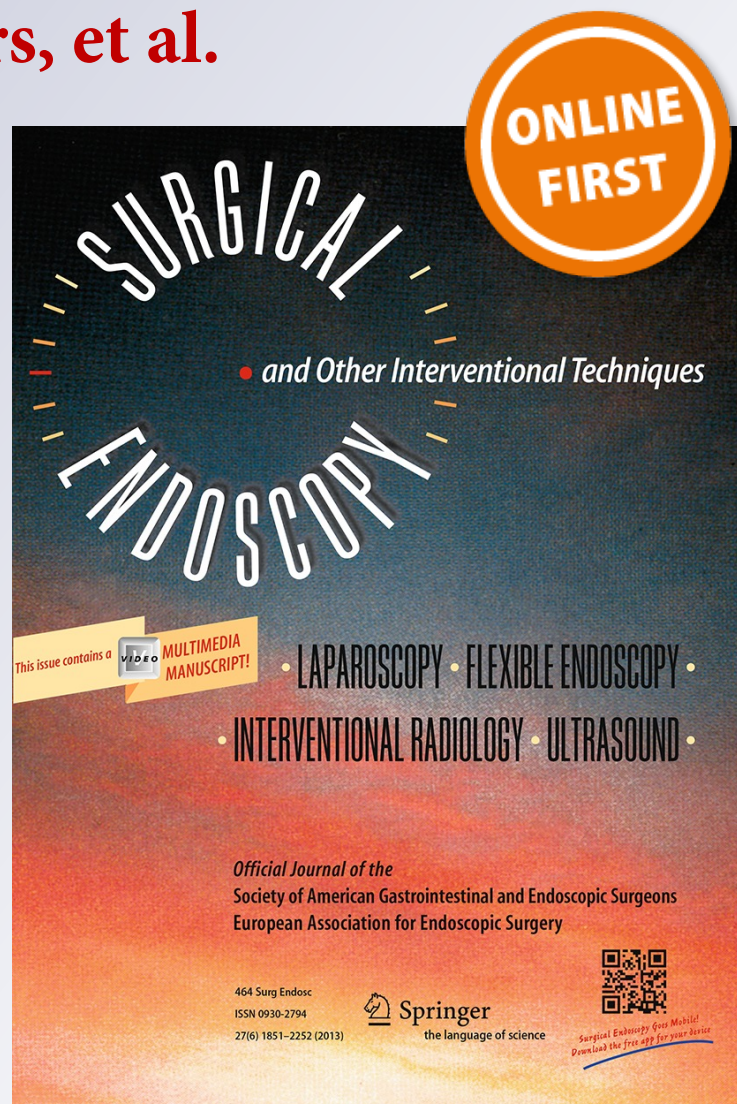
**M. M. Poelman, B. van den Heuvel,
J. D. Deelder, G. S. A. Abis, N. Beudeker,
R. R. Bittner, G. Campanelli, D. van
Dam, B. J. Dwars, et al.**

Surgical Endoscopy

And Other Interventional Techniques
Official Journal of the Society of
American Gastrointestinal and
Endoscopic Surgeons (SAGES) and
European Association for Endoscopic
Surgery (EAES)

ISSN 0930-2794

Surg Endosc
DOI 10.1007/s00464-013-3001-9



Your article is protected by copyright and all rights are held exclusively by Springer Science +Business Media New York. This e-offprint is for personal use only and shall not be self-archived in electronic repositories. If you wish to self-archive your article, please use the accepted manuscript version for posting on your own website. You may further deposit the accepted manuscript version in any repository, provided it is only made publicly available 12 months after official publication or later and provided acknowledgement is given to the original source of publication and a link is inserted to the published article on Springer's website. The link must be accompanied by the following text: "The final publication is available at link.springer.com".

EAES Consensus Development Conference on endoscopic repair of groin hernias

M. M. Poelman · B. van den Heuvel · J. D. Deelder · G. S. A. Abis · N. Beudeker · R. R. Bittner · G. Campanelli · D. van Dam · B. J. Dwars · H. H. Eker · A. Fingerhut · I. Khatkov · F. Koeckerling · J. F. Kukleta · M. Miserez · A. Montgomery · R. M. Munoz Brands · S. Morales Conde · F. E. Muysoms · M. Soltes · W. Tromp · Y. Yavuz · H. J. Bonjer

Received: 9 April 2013 / Accepted: 23 April 2013
 © Springer Science+Business Media New York 2013

Groin hernia repair is one of the most common surgeries, performed globally in more than 20 million people per year [1, 2]. Historically, the first surgeries for groin hernias were performed by the end of the 16th century [3, 4]. Repairs that involved reduction and resection of the hernial sac and enforcement of the posterior wall of the inguinal canal by approximating its muscular and fascial components were performed by the end of the 19th century. Utilization of prosthetic material was introduced in the 1960s, initially only in elderly patients with recurrent inguinal hernias.

Favorable long-term results of these mesh repairs allowed adoption of mesh repair in a larger group of patients. At the present time, the majority of surgeons prefer mesh repair of inguinal hernias.

In the early 1980s, minimally invasive techniques for groin hernia repair were first reported, adding another modality to the management of these hernias [4]. Transperitoneal laparoscopic and extraperitoneal endoscopic techniques, collectively known as endoscopic surgery, have been developed. There is considerable variation of surgical

M. M. Poelman (✉) · B. van den Heuvel · G. S. A. Abis · D. van Dam · R. M. Munoz Brands · H. J. Bonjer
 Department of Surgery, VUMC, Amsterdam, The Netherlands
 e-mail: mm.poelman@vumc.nl

B. van den Heuvel
 e-mail: baukjevdh@yahoo.com

G. S. A. Abis
 e-mail: g.abis@vumc.nl

D. van Dam
 e-mail: d.vandam@vumc.nl

R. M. Munoz Brands
 e-mail: r.munozbrands@vumc.nl

H. J. Bonjer
 e-mail: j.bonjer@vumc.nl

J. D. Deelder
 Department of Surgery, MCA, Alkmaar, The Netherlands
 e-mail: jddeelder@gmail.com

N. Beudeker · B. J. Dwars · W. Tromp
 Department of Surgery, Slotervaartziekenhuis, Amsterdam, The Netherlands
 e-mail: Nikki_b88@hotmail.com

B. J. Dwars
 e-mail: BJ.dwars@slz.nl

W. Tromp
 e-mail: woutertromp@live.nl

R. R. Bittner
 Department of General and Visceral Surgery, Marienhospital Stuttgart, Stuttgart, Germany
 e-mail: bittnerfamilie@web.de

G. Campanelli
 Department of General Surgery, Istituto Clinico Sant' Ambrogio, Milan, Italy
 e-mail: giampiero.campanelli@grupposandonato.it

H. H. Eker
 Department of Surgery, Red Cross Hospital, Beverwijk, The Netherlands
 e-mail: heker@rkz.nl

A. Fingerhut
 Visceral and Digestive Surgical Unit, Centre Hospitalier Intercommunal, Créteil, France
 e-mail: abefingerhut@aol.fr

I. Khatkov
 Department of Medicine and Dentistry, Moscow State University, Moscow, Russia
 e-mail: ihatkov@gmail.com

techniques in endoscopic repair of groin hernias, rendering development of consensus prudent.

The European Association of Endoscopic Surgery (EAES) initiated a consensus development conference with on endoscopic groin hernia surgery during its annual congress in 2012. The aim of this conference was to provide practical guidelines that used available medical evidence combined with the opinions of an expert panel and the membership of the EAES. The findings of this conference are reported here.

Methods

The coordinator of the consensus development conference (HJB) and two members of the consensus panel (BvdH and MMP) selected a group of 14 surgeons, representing the European countries, with both clinical and scientific expertise in groin hernia surgery. Six medical scientists supported this panel of experts. Key topics were presented, adapted, and eventually approved by the panel of experts. All topics were assigned to two experts and medical scientists.

The medical scientists performed a critical appraisal of the literature and selected the best available evidence on each topic. A literature search was performed of articles published from 1970 through June 2012 for each specific topic. All the articles concerning this specific topic were reviewed, and articles with the highest level of evidence (LoE) were selected. The LoE was assessed according to the Oxford classification (Table 1) [5]. The best available evidence was summarized. PubMed and the Cochrane

database were used. BvdH and MMP supervised the medical scientists and checked all the searches and summaries.

A summary of the best available evidence, including complete search and grading of the LoE of each study, was completed and distributed to the experts allotted for that particular topic 2 weeks before the first meeting in Amsterdam.

First statements were formulated (by HJB) in preparation of the first meeting. These statements and the summary of the best available evidence on each topic were given to the expert panel at the first meeting.

On April 20, 2012, fourteen members of the expert panel attended a full-day meeting. The coordinator of the consensus development conference, HJB, chaired the meeting. Each topic was discussed individually. Discussion was initiated by presenting the summary of the reviewed literature pertaining to that specific topic by one of the medical scientists. The levels of evidence of the reviewed articles as determined by the medical scientists were discussed and either confirmed or modified.

The statement was submitted to all members of the expert panel for acceptance. Statements were accepted, modified, or rejected. Subsequently, each statement was discussed and the level of agreement was determined. If the majority agreed, the statement was accepted in the consensus.

The statements and levels of evidence were distributed among all members of the expert panel after the meeting for approval. After approval, the topics and statements were posted on the EAES Web site before the annual conference of the EAES on June 22, 2012, in Brussels.

F. Koeckerling
Department of Surgery, Vivantes Klinikum Spandau,
Berlin, Germany
e-mail: ferdinand.koeckerling@vivantes.de

J. F. Kukleta
Department of Visceral Surgery, Klinik Im Park Hirslanden,
Zurich, Switzerland
e-mail: jfkukleta@bluewin.ch

M. Miserez
Department of surgery, University Hospital Leuven,
Leuven, Belgium
e-mail: marc.miserez@uz.kuleuven.ac.be

A. Montgomery
University of Lund and department of surgery,
Malmo University Hospital, Malmo, Sweden
e-mail: agneta.montgomery@skane.se

S. Morales Conde
Department of Surgery, University Hospital Virgen Macarena,
Seville, Spain
e-mail: smoralesc@gmail.com

F. E. Muysoms
Department of Surgery, Univeristy Hospital Maria Middelaers,
Ghent, Belgium
e-mail: filip.muysoms@azmmsj.be

M. Soltes
Department of Surgery, Pavol Jozef Safarik University,
Kosice, Slovakia
e-mail: soltes.marek@yahoo.com

Y. Yavuz
Department of General Surgery, Marmara University Hospital,
Istanbul, Turkey
e-mail: yunusyavuz@mac.com

Table 1 Oxford classification for levels of evidence

Level	Therapy/prevention, etiology/harm	Prognosis
1a	Systematic review (with homogeneity) of RCTs	SR of inception cohort studies; validated in different populations
1b	Individual RCT (with narrow confidence interval)	Individual inception cohort study with $\geq 80\%$ follow-up; validated in a single population
1c	All or none	All-or-none case series
2a	SR (with homogeneity) of cohort studies	SR (with homogeneity) of either retrospective cohort studies or untreated control groups in RCTs
2b	Individual cohort study (including low quality RCT; e.g., $<80\%$ follow-up)	Retrospective cohort study or follow-up of untreated control patients in an RCT
2c	“Outcomes” research; ecological studies	“Outcomes” research
3a	SR (with homogeneity) of case-control studies	
3b	Individual case-control study	
4	Case series (and poor-quality cohort and case-control studies)	Case series (and poor-quality prognostic cohort studies)
5	Expert opinion without explicit critical appraisal; or based on physiology, bench research, or “first principles”	Expert opinion without explicit critical appraisal; or based on physiology, bench research, or “first principles”

RCT randomized controlled trial, SR systematic review
See also <http://www.cebm.net>

The members of the expert panel presented all topics, statements, and associated LoE to an audience of attendees of the EAES conference. Voting pads allowed all present to vote in favor or against each statement. The level of consensus (LoC) was determined according to the classification shown in Table 2.

The conference was recorded and was posted on the EAES Web site after the congress was held. EAES members could vote in favor of or against the statement through a secure link. Two reminders to vote were sent by e-mail by the EAES secretary.

Results

One thousand eighty-one delegates from 82 countries attended the EAES congress in Brussels in 2012. Of these, between 92 and 164 surgeons voted during the consensus conference. After the conference was posted on the EAES Web site, 17 surgeons voted (at least for some statements) online.

The LoE, as determined by the expert panel, will be provided after each statement. The LoC (Table 2) is provided,

Table 2 Classification of consensus

Strength of consensus	Percentage of agreement
Strong consensus	$>95\%$ of participants
Consensus	75–95 % of participants
Majority	50–75 % of participants
No consensus	$<50\%$ of participants

including the votes in favor of the statement, the total amount of votes, and the calculated percentage.

Factors predisposing to developing groin hernias

The impact of predisposing factors on the development of groin hernias is under debate. Many clinicians assume that occasional lifting, constipation, and prostatism increase the risk for developing groin hernias. However, evidence is lacking [6, 7].

A patent processus vaginalis does predispose for developing a groin hernia [8]. Patients who have ascites, who are treated with intra-abdominal dialysis, who have COPD, and who perform long-term heavy work have an increased risk for developing a groin hernia as a result of elevated intra-abdominal pressure [6, 7]. Surgery in the lower abdomen such as an open appendectomy or prostatectomy might cause a groin hernia [6, 7].

Hernias of the abdominal wall represent weakening of the muscular and fascial layers of the abdominal wall. Collagen is an important cross-link providing strength to such tissues. Therefore, deficiencies of collagen metabolism may cause hernias. There are 12 types of collagen in the human body; the proper balance between these individual collagen types is essential to the strength of the collagen-rich tissues. Changes in the collagen metabolism can either be due to external factors like smoking or can have a genetic predisposition [6, 7]. An altered collagen metabolism manifested by a decreased type I:III collagen ratio seems to be the underlying biologic source of abdominal wall hernia formation [9].

Patients with an abdominal aortic aneurysm (AAA) have an increased propensity for abdominal wall hernia

development. In a meta-analysis [10], the correlation between AAAs and abdominal wall hernias was confirmed. The study compared the incidence of incisional and inguinal hernias in patients with AAAs to patients with aortoiliac occlusive disease and found a relative risk of inguinal hernia of 2.3 (odds ratio 2.30; 95 % confidence interval 1.52–3.48; $p < 0.0001$).

Patients with a decreased type I:III collagen metabolism and patients with an AAA are thought to share a systemic connective tissue defect affecting the structural integrity of the aortic and the abdominal wall. The exact pathogenesis is unknown.

In a Swedish cohort study [11] of 1,072 HIV-infected male patients receiving antiretroviral therapy, an increased incidence of abdominal wall hernias was reported. The underlying mechanism and cause of this finding were unknown.

Statements

1. Occasional lifting, constipation, and prostatism do not predispose to the development of groin hernia. (LoE: 3; LoC: majority, 68 of 110 = 62 %)
2. In patients with aneurysmal disease, the incidence of groin hernia is increased. (LoE: 3; LoC: majority, 60 of 115 = 52 %)

Assessment of groin hernia

In daily practice, the majority of groin hernias can be diagnosed accurately by physical examination. Imaging studies are only indicated when the presence of a groin hernia is unclear or when the clinician is unsure whether the swelling in the groin is caused by a hernia [12, 13]. However, in case of groin pain without swelling at clinical presentation, the diagnosis of a groin hernia by physical examination can be challenging [14], and additional imaging may be necessary to identify the actual groin pathology [15]. Herniography, radiography of the pelvic area after intraperitoneal injection of radio-opaque dye, has been the standard imaging procedure since 1967 [16]. However, this is an invasive procedure with an inherent risk of visceral or vascular damage. A review showed an overall sensitivity rate ranging from 81 to 100 % and a specificity rate from 92 to 98.4 %. Other noninvasive imaging modalities such as ultrasound, computed tomographic (CT) scan, and magnetic resonance imaging (MRI) have been evaluated.

A noncontrast CT scan has an overall accuracy of 94 % [17]. A small study [18] confirms the additional value of MRI when the herniography is unclear in an occult groin hernia. Correlation with surgical findings showed

ultrasound to have a sensitivity of 33 % and a specificity of 100 % [19, 20].

CT scan and MRI have the advantage over ultrasound and herniography in diagnosing other causes of groin pathology. Ultrasound has a high specificity and is cheap, and it is therefore considered the most cost-effective imaging modality in patients with groin hernia.

It is considered difficult to determine whether an inguinal hernia is direct or indirect during physical examination [21–23]. Some surgeons prefer a precise and detailed preoperative evaluation of the type of inguinal hernia and advocate the concept of individualized inguinal hernia repair [15, 24–29]. However, knowledge of the type of inguinal hernia rarely modifies the indication for surgery, and little importance is given to preoperative differentiation of inguinal hernia type. Thus, the majority of the members of the expert panel did not believe that preoperative knowledge of the type of hernia would change their surgical approach.

Statements

3. In case of clear clinical diagnosis of inguinal hernia, no additional imaging studies are necessary. (LoE: 2c; LoC: consensus, 137 of 147 = 93 %)
4. When a groin hernia is suspected but clinical findings are equivocal, the first step in imaging is dynamic ultrasonography, followed by dynamic MRI. (LoE: 2c; LoC: consensus, 138 of 149 = 93 %)
5. Ultrasonography and MRI have a high sensitivity and specificity considering the detection of an occult inguinal hernia and have replaced herniography as a diagnostic instrument. (LoE: 2c; LoC: consensus, 136 of 149 = 91 %)
6. CT can be a useful adjunct for the detection of an occult groin hernia. (LoE: 3; LoC: majority, 112 of 152 = 74 %)
7. Physical examination does not allow distinguishing direct (i.e., medial) from indirect (i.e., lateral) inguinal hernias. (LoE: 2; LoC: majority, 103 of 154 = 67 %)

Operative or conservative approach of groin hernias and selection of endoscopic technique

The general strategy toward groin hernias is surgical repair. The presenting symptom of a groin hernia is either discomfort or pain in the groin in two-thirds of all patients [30]. One-third of all patients have no symptoms at clinical presentation, but only a sign of a nontender bulge in the groin. The rationale to recommend surgery is to prevent visceral incarceration and subsequently ischemia (strangulation). However, little is known about the natural

history of untreated groin hernias [31]. Two large randomized controlled studies have been published [32, 33] to analyze the natural course of asymptomatic inguinal hernias. These studies concluded that watchful waiting was safe in asymptomatic inguinal hernias. However, a later study showed that the majority of patients with an asymptomatic inguinal hernia eventually become symptomatic, and the study concluded that the evidence for a watchful waiting policy is lacking [34]. The rationale for surgery in inguinal hernias is therefore treatment of current or future symptoms, and not to prevent incarceration.

Considering that most patients with an asymptomatic groin hernia eventually become symptomatic, an occult contralateral hernia discovered during endoscopic repair of a symptomatic unilateral hernia can be repaired during the same surgical procedure. This can only be done when this option has been discussed before surgery and informed consent has been obtained. In the absence of a groin hernia, prophylactic mesh placement on the contralateral side in endoscopic repair of a symptomatic unilateral hernia is not advisable.

Femoral hernias seem to incarcerate significantly more than inguinal hernias. The actual risk of incarceration of femoral hernias has only been described in observational cohort studies, but it shows a 7–8 fold increase compared to inguinal hernias [31, 35–38]. The rationale for surgery in femoral hernias is therefore to prevent incarceration.

Endoscopic repair can be done for all groin hernias, inguinal and femoral, unilateral and bilateral, primary and recurrent. The expert panel states that there are no absolute contraindications for endoscopic repair in adolescents aged 14–18 years. Endoscopic groin hernia in complicated situations, such as after radical prostatectomy or cystectomy, in patients with a scrotal hernia, ascites, or on peritoneal dialysis, and in cases of repeat endoscopic repairs, should only be performed by a surgeon who has a high level of experience in endoscopic groin hernia repair.

The two major endoscopic techniques are transabdominal preperitoneal repair (TAPP) and total preperitoneal repair (TEP). In the best available evidence [39, 40], no technique seems to be superior to the other with regards to outcomes and complication rates. Both techniques were associated with similar operative time, postoperative complications, postoperative pain, time to return to work, and recurrences. TAPP was associated with a slightly longer hospital stay compared with TEP.

Endoscopic groin hernia repair is favored over open groin hernia repair in certain patients. Endoscopic groin hernia repair is associated with less postoperative pain than open repair [41–44]. This difference in pain seems to disappear during the first 6 weeks after surgery. Young, active adults benefit mostly from endoscopic groin hernia repair because they gain most from early convalescence. It is

therefore stated that young active adults with a groin hernia are preferably repaired with an endoscopic technique. Endoscopic surgery is also preferred in patients with a recurrent groin hernia after open repair [40]. The posterior route is free of scar tissue, and therefore the groin can be reached more easily with an endoscopic approach.

In patients with bilateral groin hernias, the expert group stated that endoscopic repair is ideal because both groins can be reached using two or three small incisions, whereas in open repair, one large incision in each groin is necessary.

Statements

Recurrent groin hernia

8. Endoscopic surgery is preferred in patients with a recurrent groin hernia after open repair. (LoE: 1b; LoC: strong consensus, 151 of 158 = 96 %)
9. Repeat endoscopic repair is only feasible when the surgeon has a high level of experience in repeat endoscopic groin hernia repair (TAPP). (LoE: 5; LoC: consensus, 109 of 134 = 81 %)

Bilateral groin hernia

10. Especially in bilateral groin hernia, endoscopic surgery is an excellent approach. (LoE: 5 for TEP/2b for TAPP; LoC: strong consensus, 154 of 161 = 96 %)
11. Concerning the repair of (a bilateral) groin hernia, there is no clear advantage of TEP over TAPP or vice versa. (LoE: 2a; LoC: majority, 105 of 142 = 73 %)
12. When an occult contralateral hernia is discovered during endoscopic repair of a symptomatic unilateral hernia, the occult and the symptomatic hernia can be repaired in the same surgical procedure. (LoE: 5; LoC: strong consensus, 148 of 154 = 96 %)
13. In the absence of a groin hernia, prophylactic mesh placement on the contralateral side in endoscopic repair of a symptomatic unilateral hernia is not advisable. (LoE: 5; LoC: consensus, 124 of 138 = 90 %)

Endoscopic repair in a complex situation

14. In complex situations, endoscopic hernia repair should only be considered when the surgeon has a high level of experience in endoscopic groin hernia repair (LoE: 5; LoC: consensus, 135 of 152 = 89 %). The following situations are considered to be (highly) complex: patients after radical prostatectomy or cystectomy, and patients with a scrotal hernia, ascites, previous posterior mesh repair, or peritoneal dialysis

Endoscopic repair in the young individual

15. Groin hernias in young, active adults are preferably repaired with an endoscopic technique. (LoE: 1a; LoC: consensus, 112 of 148 = 76 %)
16. There are no absolute contraindications for endoscopic repair in adolescents aged 14–18 years. (LoE: 5; LoC: majority, 96 of 150 = 64 %)

Endoscopic repair of femoral hernias

17. Endoscopic repair is the preferred surgical approach in case of a femoral hernia. (LoE: 5 men/2c women; LoC: consensus, 108 of 144 = 75 %)

Endoscopic repair of strangulated hernia

The definitions of the terms *strangulation* and *incarceration* vary. The EAES consensus group adheres to the following definition: strangulation indicates that there is a bulge in the hernia sac, with compromised blood supply to the strangulated viscera. Incarceration indicates a nonreducible bulge in the groin that can either be symptomatic or asymptomatic.

Strangulated groin hernias or symptomatic incarcerated hernias should be operated on urgently to prevent ischemia of the incarcerated viscera. In case of strangulation or symptomatic incarceration, the intra-abdominal cavity should be inspected, followed by either TEP or TAPP [45].

Some surgeons dread the use of a mesh in emergency hernia repair, particularly when a bowel resection is required, because of the fear for a mesh infection. However, there is insufficient evidence to avoid mesh repair in these situations routinely. Studies have demonstrated few to no mesh infections in patients who underwent bowel resection during an emergency endoscopic procedure [46, 47].

A trial was performed randomizing patients with spontaneously reduced strangulated groin hernias to either laparoscopic inspection of the hernia sac and abdominal cavity or to open inspection of the hernia sac with or without explorative laparotomy (at the surgeon's discretion) [48]. In the laparoscopy group, 2 of 21 patients had resections of a necrotic ileal bowel loop during abdominal inspection. In the open group, 4 of 20 patients had explorative laparotomy with 2 of 4 bowel resections. One patient in the open group had a delayed laparotomy because of missed bowel ischemia.

Overall, the endoscopic approach of incarcerated and strangulated groin hernias allows for laparoscopic inspection of the intra-abdominal cavity in all patients and hence

could prevent missed bowel ischemia. A diagnostic laparoscopy is preferred, followed by an endoscopic repair, in selected cases.

Statements

18. Repair of incarcerated, nonreducible groin hernias has to be done urgently and can be performed with an endoscopic technique. (LoE: 2a; LoC: consensus, 124 of 155 = 81 %)
19. When performing an endoscopic repair, the abdominal cavity should be inspected followed by either TAPP or TEP. (LoE: 5; LoC: consensus, 113 of 123 = 92 %)
20. Mesh placement during surgery for strangulated groin hernia is possible in clean-contaminated situations (i.e., in case of a bowel resection). (LoE: 2a; LoC: majority, 103 of 150 = 69 %)
21. In cases of suspicion of a strangulated groin hernia, a diagnostic laparoscopy is preferred. (LoE: 5; LoC: majority, 109 of 149 = 73 %)

Endoscopic repair of sportsman's hernia

Among professional athletes, groin pain is a common injury. Causes for chronic groin pain are lumbar spine problems such as compression syndrome and herniated lumbar disc, leg length differences, tendinitis of the adductor muscle, osteitis pubis, prostatitis, and sportsman's hernia. In athletes with chronic groin pain, a sportsman's hernia can be diagnosed only when other causes have been excluded [49]. Because of the large differential diagnosis of groin pain in athletes, it is extremely important to evaluate each patient in whom a sportsman's hernia is suspected in a multidisciplinary setting.

Various imaging techniques are used to diagnose a sportsman's hernia or to exclude other causes of groin pain [50]. The expert panel agreed that MRI is the preferred imaging technique because of its capacity to differentiate between several groin pathologies. MRI has the advantage of using magnetic fields instead of X-rays, but it is expensive and has never been proven to be the best technique to diagnose groin hernias.

Several studies have been undertaken over the past few years to define the best treatment method for sportsman's hernia. In a prospective randomized setting, the endoscopic TEP mesh placement was compared with conservative therapy (i.e., rest, physiotherapy, steroid injections, oral anti-inflammatory analgesics) in 60 athletes with a groin hernia [51]. This study reported that operative repair was more effective than nonoperative treatment for chronic pain after 1 up to 12 months of follow-up ($p < 0.001$).

Ninety percent of the patients who underwent surgery returned to sports activities after 3 months compared to 27 % in the conservative group ($p < 0.001$). Two studies [50, 52] treated athletes with chronic groin pain unresponsive to conservative treatment with TEP. In these study groups, 93 to 100 % returned to full sports activity 3 months after TEP repair.

Statements

22. A multidisciplinary team should evaluate possible sportsman's hernia in order to exclude other causes of groin pain such as lumbar spine problem (compression syndrome, herniated lumbar disc), leg length differences, tendinitis of the adductor muscle, osteitis pubis, or prostatitis. MRI is the preferred imaging modality. (LoE: 5; LoC: consensus, 141 of 161 = 88 %)
23. Endoscopic placement of a mesh in the groin is effective in athletes with a sportsman's hernia. (LoE: 1b; LoC: consensus, 129 of 147 = 88 %)

Antibiotic prophylaxis

There is little evidence for the use of antibiotics during endoscopic groin hernia repair [53]. In open groin hernia repair, the effectiveness of antibiotic prophylaxis in reducing postoperative wound infection rates has been studied extensively. In 2012, a large Cochrane review was published concerning this subject. It included 7,843 patients from 17 randomized controlled trials. It was concluded that no universal recommendation for antibiotic prophylaxis could be provided; nor could it be recommended against when high infection rates are observed [54].

Statements

24. There is not enough evidence to support the routine use of prophylactic antibiotics in elective endoscopic groin repair. (LoE: 5; LoC: consensus, 123 of 162 = 76 %)

Procedural and technical aspects of endoscopic groin hernia repair

The particular technical details of TEP and TAPP groin hernia repair are beyond the aim of this article. The choice and fixation of the mesh and how to approach the absence of a hernia sac during surgery will be discussed.

To evaluate the type of mesh used during endoscopic groin hernia repair, a meta-analysis of lightweight mesh versus heavyweight mesh in both TEP and TAPP inguinal hernia repair was performed [55]. Eight randomized clinical trials were included [56–62], and a total of 1,667 hernias in 1,592 patients were analyzed. The mean study follow-up was between 2 and 60 months. No significant effect on recurrence, chronic pain, postoperative pain, seroma formation, or return to work was found, and both meshes appeared to result in similar long- and short-term postoperative outcomes. Future long-term analysis of recurrence and postoperative chronic pain may guide surgeon selection of mesh weight for endoscopic groin hernia repair.

Mesh fixation technique is a frequently studied topic because postoperative pain has become one of the major outcomes in inguinal hernia surgery. In TAPP repair, the mesh is usually fixed with glue, tackers, or staples. In TEP repair, the mesh is not fixed at all, or is fixed with glue, tackers, or staples.

Several studies have been published concerning the difference between glue and tacker fixation in TAPP hernia repair with regard to the incidence of recurrences [63–67]. The type of fixation did not influence the recurrence rate. Also, the type of fixation did not seem to influence acute or chronic pain [64–68]. Some studies suggest that tacker fixation may lead to higher acute and chronic pain scores, but other studies repudiate this [66].

Three groups performed meta-analyses of the influence of fixation versus nonfixation of the mesh in TEP repair [69–71]. Only one group reported a difference in chronic postoperative pain favoring the nonfixation group [71]. The other two [69, 70] did not find any difference in recurrence rate or (chronic) pain. A randomized controlled trial (that was not included in these meta-analyses) [72] compared postoperative pain between fixation and nonfixation of the mesh and did not show any difference in acute or chronic pain. Moreover, the incidence and amount of postoperative pain is also likely to be influenced by the number and location of tackers/staples.

The expert group agreed that diverse types of inguinal hernias (i.e., direct vs. indirect and large vs. small hernias) should be distinguished and treated in a different way. Randomized controlled trials have not differentiated between large and small hernias; the use of a lightweight mesh with or without fixation of the mesh in case of a large direct (medial) hernia might lead to a higher recurrence rate.

A prevalent phenomenon during endoscopic repair of a groin hernia is the absence of a hernia sac. Patients present with a bulge in the groin, but no sac is found during surgical exploration. Even when a sac is absent, herniation through the abdominal wall is not excluded. Preperitoneal

fatty tissue could protrude through an insufficient fascia transversalis as a direct hernia or through the internal ring along the spermatic cord as an indirect hernia. Inguinal lipomas are therefore considered to be a pitfall in hernia surgery [73]. The incidence of an inguinal lipoma is around 20 % and might be related to body mass index [74–76].

Statements

25. Sufficient overlap of the mesh is more important than fixation of the mesh. (LoE: 5; LoC: consensus, 116 of 141 = 82 %).
26. There is currently not enough evidence supporting the general use of lightweight mesh over heavyweight mesh in endoscopic groin hernia repair. (LoE: 1a; LoC: consensus, 127 of 147 = 86 %)
27. The mesh in groin hernia repair measures minimally 15 × 10 cm. (LoE: 5 TEP/2c TAPP; LoC: consensus, 136 of 153 = 89 %)
28. The use of a heavy weight mesh, larger mesh size, mechanical fixation, and reduction of dead space (i.e., fixation of the transversalis fascia) could be considered in patients with a large medial (i.e., direct) hernia. (LoE: 5; LoC: consensus, 121 of 142 = 85 %)
29. Tacker or suture fixation for groin hernia (with the exception of large direct inguinal hernias) should be avoided. (LoE: 5; LoC: majority, 104 of 158 = 66 %)
30. In all endoscopic groin hernia repairs, an active search for herniating lipomas should be done. (LoE: 5; LoC: consensus, 136 of 172 = 79 %)
31. Herniated adipose tissue present in the internal ring should be reduced. (LoE: 5; LoC: consensus, 125 of 135 = 93 %)

Complications of endoscopic groin hernia repair

Complications after endoscopic groin hernia repair are widely described. The most common short-term complication is formation of a hematoma or a seroma. The average incidence of hematoma reported in several randomized controlled trials is around 8 % [40, 42, 77–85]. The incidence of a postoperative seromas after endoscopic repair is approximately 7 %. It is of great importance to inform patients about the possibility of seroma formation, as seroma is not a rare adverse effect. Patients might confuse the swelling formed by the seroma as a persistent groin hernia and might conclude that surgery has failed. However, seroma formation most often lacks clinical significance or clinical relevance. Therefore, all panel members agreed that when seroma formation occurs, there is generally no need for aspiration.

In contrast to complications such as hematoma and seroma, wound infection after endoscopic repair occurs rarely, with reported rates of approximately 1 % [40, 42, 77, 79–83, 85–87]. Mesh infection rarely occurs. A Cochrane review found that only one mesh infection occurred in 2,179 patients who underwent endoscopic groin hernia repair [40]. The expert panel agreed that in case of a mesh infection, removal of the mesh is generally not necessary.

A frequently mentioned drawback of laparoscopic repair of an inguinal hernia is the possible collateral damage of vital adjacent structures such as bowels or vessels. The incidence of serious collateral damage might be higher during the surgeon's learning curve.

Some studies show that the incidence of vascular and visceral damage is slightly higher in endoscopic groin repair compared to open groin hernia repair. Vascular damage was reported in 0.14 % in TAPP versus none in TEP and open repair. Visceral damage was reported in 0.65 % in TAPP, 0.16 % in TEP, and 0.14 % in open repair [88]. However, a large meta-analysis in 2005 comparing laparoscopic inguinal hernia repair versus open repair that included about 3,500 repairs and analyzed the incidence of collateral damage did not find any significant difference. In the laparoscopic group (TAPP/TEP), an incidence was documented of 0.1 % of intraoperative bowel lesions, versus 0.06 % in the open group. This difference was not significant. The incidence of vascular damage in the laparoscopic group was 0.09 % versus none in the open. This difference was also not significant [79].

The most common long-term complications are recurrence and (chronic) pain. The recurrence rate after endoscopic surgery is consistently low and varies between 0 and 5 % [77, 89–91] in randomized trials. Chronic pain, on the other hand, is a more common adverse outcome of (endoscopic) hernia repair and lacks a uniform definition. Incidences therefore vary widely, and rates as high as 25 % are reported [77]. The expert panel agreed that a proper meta-analysis of the vast numbers of studies is needed.

Quality of life and incidence of (acute) pain differ from one technique to the other and might be influenced by fixation of the mesh and type of mesh. Most studies comparing the effect of open and laparoscopic repair of inguinal hernia on quality of life and pain favor the latter because of a reduction in acute pain [77, 92–95]. However, the difference in postoperative pain scores in favor of the laparoscopic approach diminishes over time.

Recently, more attention has been paid to the effect of mesh repair on male fertility. Testicular atrophy due to impaired vascularization and hydrocele are identified as long-term complications after inguinal hernia repair [83, 96, 97]. One study suggests that the use of a lightweight mesh in TEP negatively influences sperm motility [59]. However, in a large epidemiologic study, no association

was found between inguinal hernia repair and increased incidence of infertility [98].

Statements

Short-term complications

32. Infections of the mesh rarely occur after endoscopic groin hernia repair (LoE 1a). In case of mesh infection, removal of the mesh is generally not necessary (LoE 5). (LoE: 1a/5; LoC: majority, 103 of 150 = 69 %)
33. Formation of a seroma is a frequent occurrence after endoscopic groin hernia repair but lacks clinical relevance or significance in most cases. It is advised to explain the possibility of seroma formation to the patient before surgery to prevent anxiety. (LoE: 5; LoC: consensus, 146 of 155 = 94 %)
34. In general, the aspiration of a seroma is not advised. (LoE: 5; LoC: consensus, 129 of 157 = 82 %)
35. Endoscopic surgeons should strive for wound infection rates below 2 % after endoscopic groin hernia repair. (LoE: 5; LoC: consensus, 102 of 111 = 92 %)

Long-term complications

36. Endoscopic surgeons should strive for symptomatic recurrence rates below 5 % five years after endoscopic groin hernia repair. (LoE: 5; LoC: consensus, 130 of 142 = 92 %)
37. Endoscopic surgeons should strive for severe chronic groin pain rates below 2 % five years after endoscopic groin hernia repair. (LoE: 5; LoC: consensus, 99 of 120 = 83 %)
38. Mesh repair in general does not seem to cause infertility in men. (LoE: 2c; LoC: consensus, 133 of 145 = 92 %)

Postoperative considerations in endoscopic groin hernia repair

The general approach towards physical restrictions after groin hernia repair differs considerably [99]. Many surgeons and general practitioners recommend a few weeks of rest, including no driving, working, or lifting. However, those recommendations seem to depend more on local tradition than clear evidence and therefore need to be reconsidered [100].

Studies failed to show any disadvantageous effect of a short period of convalescence with regard to the development of a recurrence [101–105]. Early and active encouragement of patients after groin hernia repair is associated

with shortened convalescence and earlier return to work [104]. Hand and foot reaction times return to preoperative levels 7–10 days after surgery [106, 107].

The value of follow-up after inguinal hernia repair is unclear. Most studies on this subject stress the importance of prolonged follow-up for quality assessment of inguinal hernia surgery. These studies use postal questionnaires to select patients with a suspected recurrence with varying degrees of success [108–110]. No studies were found on the need for regular checkups after inguinal hernia repair to detect asymptomatic recurrences or to prevent incarceration. Therefore, routine follow-up after groin hernia surgery lacks medical evidence.

Quality assessment after endoscopic inguinal hernia surgery consists of two long-term complications: recurrence and pain. A variety of questionnaires and tools are being used to assess the quality of life and pain after inguinal hernia repair.

Traditionally, quality of life measurements after surgery were conducted using the generic Short Form-36 (SF-36) [111]. The SF-36 is thought to be an adequate tool to measure quality of life in patients over time, but it is too extended and universal to measure specific complaints after a specific treatment. In addition to general health-related quality of life instruments as the SF-36, disease-specific instruments focus on particular health conditions and are useful to detect the changes resulting from specific treatment. The Carolina Comfort Scale (CCS) was developed as a disease-specific questionnaire for evaluating quality of life after mesh hernia repair [112]. It evaluates the sensation of the mesh, pain, and movement limitation in different aspects of common daily life. Another disease-specific questionnaire has been proposed [113], but it has not yet been validated. The expert panel agreed that an internationally accepted hernia-specific questionnaire to monitor pain and discomfort after inguinal hernia repair is necessary.

For the evaluation of pain, the visual analog scale is often used, although the verbal rating scale might be better for postherniorrhaphy pain assessment [114]. The visual analog scale for pain can be used when specific cutoff points are used to define mild, moderate, and severe pain. Another questionnaire that has been used for pain-assessment is the Inguinal Pain Questionnaire, which has been proven a reliable instrument to assess pain after inguinal hernia repair [115].

Statements

Patient encouragement/advice

39. Active encouragement after groin hernia repair is associated with shortened convalescence. (LoE: 3; LoC: consensus, 86 of 110 = 78 %)

40. Early activity after groin hernia repair does not seem to increase recurrence rates. (LoE: 3; LoC: consensus, 125 of 159 = 79 %)

Follow-up

41. Routine follow-up after (endoscopic) groin hernia repair is not necessary. (LoE: 5; LoC: consensus, 67 of 126 = 53 %). (The Consensus Conference Brussels found that follow-up is necessary to assess incidence of recurrence and chronic pain.)

Quality of life

42. Quality of life after endoscopic hernia repair is generally excellent in most patients. (LoE: 1a; LoC: consensus, 138 of 153 = 88 %)

Educational, organizational, and financial aspects of endoscopic groin hernia repair

Competency in surgery is of great importance for patient safety. In endoscopic surgery of groin hernias, competency has not been consistently defined. Hence, it is very difficult to determine the criteria for reaching full competency. Endoscopic groin hernia repair is considered more difficult than open groin hernia repair. The number of procedures needed to reach full competence (that is, the learning curve) is dependent on several factors such as previous experience and type of training method.

The existing literature reflects mostly series of hernia surgeries performed by a single surgeon or a small group of surgeons who adopted the technique of endoscopic surgical repair of hernias in a nonstructured fashion. The results of individual surgeons have been analyzed in large retrospective [116–118] and prospective [119, 120] studies. These studies showed significant reduction of operating times, conversion rates, and complication rates after 30–100 TEP procedures and 50–75 TAPP procedures. These studies reveal that the number of cases required to accomplish competency is determined by various factors such as previous experience with other minimally invasive procedures and experience in open groin hernia surgery.

An American group [121, 122] demonstrated that surgeons in training reach competence after fewer cases in a structured educational program. Development of structured training programs is therefore mandatory to improve the efficacy of educational modules and to increase patient safety.

Clear evidence supporting centralization of hernia repair in specialized hospitals is not available. However, one study [121] demonstrated that centralization of hernia repair within one hospital by referring all patients with hernias to a single dedicated surgeon resulted in fewer wound infections (5.9–0.45 %, $p < 0.005$), fewer systemic complications (2.05–0.45 %, $p < 0.05$), and lower recurrence rates (4.6–0.45 %, $p < 0.001$).

The use of evidence-based protocols for hernia repair result in lower perioperative complications rates (2.16 %) and lower recurrence rates (0.78 %) [123]. These results favor specialization in and centralization of hernia care.

Endoscopic groin hernia repair is more expensive compared to open groin hernia repair. The increased costs are particularly the result of the need for special equipment and general anesthesia. Costs of disposable devices and operating time can be calculated accurately, but determination of costs of personnel and amortization of nondisposable equipment is more difficult. Calculation of indirect costs is even more complex because methods of estimating lost income vary. In the available literature, the direct medical costs of laparoscopic inguinal hernia repair were higher than those of open repair [41, 77, 78, 92, 124–136]. When including societal costs, total costs were often similar or lower after endoscopic repair in many studies [6, 95, 137–141]. However, one study showed that overall, TEP is more expensive than open groin hernia repair [41]. Costs will become progressively important in health care. Overall calculation of costs, however, is complex and is therefore prone to bias.

Statements

Training and competency in endoscopic groin hernia repair

43. Endoscopic groin hernia repair is considered to be more complex than open groin hernia repair. (LoE: 2c; LoC: consensus, 115 of 142 = 81 %)
44. Broad implementation of a structured educational program in endoscopy is recommended to familiarize surgeons in training with endoscopic surgery and to prevent rare but serious complications of vascular damage or bowel perforation. (LoE: 5; LoC: strong consensus, 126 of 133 = 95 %)
45. Numbers needed to reach competence in endoscopic groin hernia repair will decrease when participating in a structured educational program. (LoE: 2c; LoC: strong consensus, 127 of 133 = 95 %)
46. Specializing in groin hernia repair promotes standardizing perioperative care, which reduces morbidity and lowers the recurrence rate. (LoE: 2c; LoC: consensus, 101 of 132 = 77 %)

47. Numbers needed to reach competence in TAPP repair appear to be lower than for TEP repair. (LoE: 3c; LoC: consensus, 89 of 108 = 82 %)

Costs

48. Total costs of endoscopic groin hernia repair appear to be similar to those of open repair; direct costs are higher and indirect costs are lower. (LoE: 1a; LoC: majority, 86 of 117 = 74 %)

Discussion

Consensus, which we defined as agreement among at least 75 % of participants in the consensus conference, was reached in three-quarters (36 of 48) of the statements. Five of 36 statements with consensus were supported by level 1 evidence and 21 statements with consensus were based on level 5 evidence, illustrating the paucity of high-level evidence for endoscopic repair of groin hernias. Interestingly, consensus was reached in 63 % of the level 1 statements (5 of 8) and in 84 % (21 of 25) of the level 5 statements. Apparently, high LoE statements are not consistently associated with strong consensus of the surgical community and vice versa.

The existing guidelines published by the European Hernia Society (EHS) and the International Endo Hernia Society (IEHS) both are based on review of the literature by a small group of experts without formal contributions of their members. Several surgical scientists of the EHS and IEHS were included in the expert panel of the EAES consensus development conference to ensure a platform consisting of representatives from all societies with a special focus on groin hernia surgery. Combining medical evidence with the opinions of both experts and the surgical community provides a unique method to develop best practice guidelines.

A limitation of this study is the involvement of less than 10 % (of ~2,700) EAES members. To increase involvement, the statements of the consensus development conference were posted on the EAES Web site 4 weeks before the meeting in Brussels. In addition, a recording of the consensus development conference was posted on the EAES Web site after the meeting with a digital voting module to allow members who could not attend the conference to contribute. In spite of the small number of members who used this opportunity, the use of digital communication methods deserves further attention to reach out to those who cannot readily attend conferences in person.

In conclusion, more than three-quarters of surgeons involved in the 2012 EAES consensus development

conference agreed on three-quarters of 48 statements regarding endoscopic repair of groin hernias. Collaboration between all societies with a focus on groin hernias such as the EAES, EHS, and IEHS; high-caliber scientific studies (i.e., randomized controlled trials and registries) on groin hernias; and inclusion of the opinions and experiences of the surgical community at large are all elements to further improve the quality of care for our patients with groin hernias.

Disclosures M. Poelman, B. van den Heuvel, J. Deelder, G. Abis, N. Beudeker, R. Bittner, G. Campanelli, D. Dam, B. Dwars, H. Eker, A. Fingerhut, I. Khatkov, F. Koeckerling, J. Kukleta, M. Miserez, A. Montgomery, R. M. Munoz Brands, S. Morales Conde, F. E. Muijs, M. Soltjes, W. Tromp, Y. Yavuz, and H. J. Bonjer have no conflicts of interest or financial ties to disclose.

References

1. Kingsnorth A, LeBlanc K (2003) Hernias: inguinal and incisional. *Lancet* 362(9395):1561–1571
2. Rutkow IM (2003) Demographic and socioeconomic aspects of hernia repair in the United States in 2003. *Surg Clin North Am* 83(5):1045–1051
3. Sachs M, Damm M, Encke A (1997) Historical evolution of inguinal hernia repair. *World J Surg* 21(2):218–223
4. Lau WY (2002) History of treatment of groin hernia. *World J Surg* 26(6):748–759
5. OCEBM Levels of Evidence Working Group (2011) The Oxford levels of evidence 2. Oxford Centre for Evidence-based Medicine. <http://www.cebm.net/index.aspx?o=5653>
6. Simons MP, Aufenacker T, Bay-Nielsen M, Bouillot JL, Campanelli G, Conze J, de Lange D, Fortelny R, Heikkinen T, Kingsnorth A, Kukleta J, Morales-Conde S, Nordin P, Schumpelick V, Smedberg S, Smietanski M, Weber G, Miserez M, Simons MP, Simons MP (2009) European Hernia Society guidelines on the treatment of inguinal hernia in adult patients. *Hernia* 13(4):343–403
7. Bittner R, Arregui ME, Bisgaard T, Dudai M, Ferzli GS, Fitzgibbons RJ, Fortelny RH, Klinge U, Koeckerling F, Kuhry E, Kukleta J, Lomanto D, Misra MC, Montgomery A, Morales-Conde S, Reinhold W, Rosenberg J, Sauerland S, Schug-Pass C, Singh K, Timoney M, Weyhe D, Chowbey P (2011) Guidelines for laparoscopic (TAPP) and endoscopic (TEP) treatment of inguinal hernia [International Endohernia Society (IEHS)]. *Surg Endosc* 25(9):2773–2843
8. van Veen RN, van Wessem KJ, Halm JA, Simons MP, Plaisier PW, Jeekel J, Lange JF (2007) Patent processus vaginalis in the adult as a risk factor for the occurrence of indirect inguinal hernia. *Surg Endosc* 21(2):202–205
9. Henriksen NA, Yadete DH, Sorensen LT, Agren MS, Jorgensen LN (2011) Connective tissue alteration in abdominal wall hernia. *Br J Surg* 98(2):210–219
10. Antoniou GA, Georgiadis GS, Antoniou SA, Granderath FA, Giannoukas AD, Lazarides MK (2011) Abdominal aortic aneurysm and abdominal wall hernia as manifestations of a connective tissue disorder. *J Vasc Surg* 54(4):1175–1181
11. Sundström A, Mortimer O, Akerlund B, Karlsson A, Flamholc L, Håkangård C, Granholm H, Persson I, Morfeldt L (2010) Increased risk of abdominal wall hernia associated with

- combination anti-retroviral therapy in HIV-infected patients—results from a Swedish cohort-study. *Pharmacoepidemiol Drug Saf* 19(5):465–473
12. Kraft BM, Kolb H, Kuckuk B, Haaga S, Leibl BJ, Kraft K, Bittner R (2003) Diagnosis and classification of inguinal hernias. *Surg Endosc* 17(12):2021–2024
 13. van den Berg JC, de Valois JC, Go PM, Rosenbusch G (1999) Detection of groin hernia with physical examination, ultrasound, and MRI compared with laparoscopic findings. *Invest Radiol* 34(12):739–743
 14. McIntosh A, Hutchinson A, Roberts A, Withers H (2000) Evidence-based management of groin hernia in primary care—a systematic review. *Fam Pract* 17(5):442–447
 15. Djuric-Stefanovic A, Saranovic D, Ivanovic A, Masulovic D, Zuvella M, Bjelovic M, Pesko P (2008) The accuracy of ultrasonography in classification of groin hernias according to the criteria of the unified classification system. *Hernia* 12(4):395–400
 16. Ng TT, Hamlin JA, Kahn AM (2009) Herniography: analysis of its role and limitations. *Hernia* 13(1):7–11
 17. Garvey JF (2012) Computed tomography scan diagnosis of occult groin hernia. *Hernia* 16(3):307–314
 18. Leander P, Ekberg O, Sjöberg S, Kesek P (2000) MR imaging following herniography in patients with unclear groin pain. *Eur Radiol* 10(11):1691–1696
 19. Lilly MC, Arregui ME (2002) Ultrasound of the inguinal floor for evaluation of hernias. *Surg Endosc* 16(4):659–662
 20. Alam A, Nice C, Uberoi R (2005) The accuracy of ultrasound in the diagnosis of clinically occult groin hernias in adults. *Eur Radiol* 15(12):2457–2461
 21. Conaghan P, Hassanally D, Griffin M, Ingham Clark C (2004) Where exactly is the deep inguinal ring in patients with inguinal hernias? *Surg Radiol Anat* 26(3):198–201
 22. Sanjay P, Fulke JL, Shaikh IA, Woodward A (2010) Anatomical differentiation of direct and indirect inguinal hernias: is it worthwhile in the modern era? *Clin Anat* 23:848–850
 23. Burkhardt JH, Arshanskiy Y, Munson JL, Scholz FJ (2011) Diagnosis of inguinal region hernias with axial CT: the lateral crescent sign and other key findings. *Radiographics* 31(2):E1–E12
 24. Leibl BJ, Schmedt CG, Kraft K, Ulrich M, Bittner R (2000) Scrotal hernias: a contraindication for an endoscopic procedure? Results of a single-institution experience in transabdominal preperitoneal repair. *Surg Endosc* 14(3):289–292
 25. Zhang GQ, Sugiyama M, Hagi H, Urata T, Shimamori N, Atomi Y (2001) Groin hernias in adults: value of color Doppler sonography in their classification. *J Clin Ultrasound* 29(8):429–434
 26. Kingsnorth AN, Porter CS, Bennett DH, Walker AJ, Hyland ME, Sodergren S (2000) Lichtenstein patch or Perfix plug-and-patch in inguinal hernia: a prospective double-blind randomized controlled trial of short-term outcome. *Surgery* 127(3):276–283
 27. Zollinger RM (2004) An updated traditional classification of inguinal hernias. *Hernia* 8(4):318–322
 28. Nyhus LM (1993) Individualization of hernia repair: a new era. *Surgery* 114(1):1–2
 29. Nyhus LM (2004) Classification of groin hernia: milestones. *Hernia* 8(2):87–88
 30. Hair A, Paterson C, Wright D, Baxter JN, O'Dwyer PJ (2001) What effect does the duration of an inguinal hernia have on patient symptoms? *J Am Coll Surg* 193(2):125–129
 31. van den Heuvel B, Dwars BJ, Klassen DR, Bonjer HJ (2011) Is surgical repair of an asymptomatic groin hernia appropriate? A review. *Hernia* 15(3):251–259
 32. O'Dwyer PJ, Norrie J, Alani A, Walker A, Duffy F, Horgan P (2006) Observation or operation for patients with an asymptomatic inguinal hernia: a randomized clinical trial. *Ann Surg* 244(2):167–173
 33. Fitzgibbons RJ Jr, Giobbie-Hurder A, Gibbs JO, Dunlop DD, Reda DJ, McCarthy M Jr, Neumayer LA, Barkun JS, Hoehn JL, Murphy JT, Sarosi GA Jr, Syme WC, Thompson JS, Wang J, Jonasson O (2006) Watchful waiting vs repair of inguinal hernia in minimally symptomatic men: a randomized clinical trial. *JAMA* 295(3):285–292
 34. Chung L, Norrie J, O'Dwyer PJ (2011) Long-term follow-up of patients with a painless inguinal hernia from a randomized clinical trial. *Br J Surg* 98(4):596–599
 35. Dahlstrand U, Wollert S, Nordin P, Sandblom G, Gunnarsson U (2009) Emergency femoral hernia repair: a study based on a national register. *Ann Surg* 249(4):672–676
 36. Dahlstrand U, Sandblom G, Nordin P, Wollert S, Gunnarsson U (2011) Chronic pain after femoral hernia repair: a cross-sectional study. *Ann Surg* 254(6):1017–1021
 37. Heydorn WH, Velanovich V (1990) A five-year US Army experience with 36,250 abdominal hernia repairs. *Am Surg* 56(10):596–600
 38. Gallegos NC, Dawson J, Jarvis M, Hobsley M (1991) Risk of strangulation in groin hernias. *Br J Surg* 78(10):1171–1173
 39. Bracale U, Melillo P, Pignata G, Di Salvo E, Rovani M, Merola G, Pecchia L (2012) Which is the best laparoscopic approach for inguinal hernia repair: TEP or TAPP? A systematic review of the literature with a network meta-analysis. *Surg Endosc* 26(12):3355–3366
 40. McCormack K, Scott NW, Go PM, Ross S, Grant AM, EU Hernia Trialists Collaboration (2003) Laparoscopic techniques versus open techniques for inguinal hernia repair. *Cochrane Database Syst Rev* 1:CD001785
 41. Eklund A, Carlsson P, Rosenblad A, Montgomery A, Bergkvist L, Rudberg C, Swedish Multicentre Trial of Inguinal Hernia Repair by Laparoscopy (SMIL) Study Group (2010) Long-term cost-minimization analysis comparing laparoscopic with open (Lichtenstein) inguinal hernia repair. *Br J Surg* 97(5):765–771
 42. Gong K, Zhang N, Lu Y, Zhu B, Zhang Z, Du D, Zhao X, Jiang H (2011) Comparison of the open tension-free mesh-plug, transabdominal preperitoneal (TAPP), and totally extraperitoneal (TEP) laparoscopic techniques for primary unilateral inguinal hernia repair: a prospective randomized controlled trial. *Surg Endosc* 25(1):234–239
 43. Eker HH, Langeveld HR, Klitsie PJ, van't Riet M, Stassen LP, Weidema WF, Steyerberg EW, Lange JF, Bonjer HJ, Jeekel J (2012) Randomized clinical trial of total extraperitoneal inguinal hernioplasty vs Lichtenstein repair: a long-term follow-up study. *Arch Surg* 147(3):256–260
 44. Mesci A, Korkmaz B, Dinckan A, Colak T, Balci N, Ogunc G (2012) Digital evaluation of the muscle functions of the lower extremities among inguinal hernia patients treated using three different surgical techniques: a prospective randomized study. *Surg Today* 42(2):157–163
 45. Deeba S, Purkayastha S, Paraskevas P, Athanasiou T, Darzi A, Zacharakis E (2009) Laparoscopic approach to incarcerated and strangulated inguinal hernias. *JSLs* 13(3):327–331
 46. Atila K, Guler S, Inal A, Sokmen S, Karademir S, Bora S (2010) Prosthetic repair of acutely incarcerated groin hernias: a prospective clinical observational cohort study. *Langenbecks Arch Surg* 395(5):563–568
 47. Leibl BJ, Schmedt CG, Kraft K, Kraft B, Bittner R (2001) Laparoscopic transperitoneal hernia repair of incarcerated hernias: is it feasible? Results of a prospective study. *Surg Endosc* 15(10):1179–1183
 48. Sgourakis G, Radtke A, Sotiropoulos GC, Dedemadi G, Karaliotas C, Fouzas I, Karaliotas C (2009) Assessment of strangulated content of the spontaneously reduced inguinal hernia via hernia sac laparoscopy: preliminary results of a prospective

- randomized study. *Surg Laparosc Endosc Percutan Tech* 19(2): 133–137
49. Caudill P, Nyland J, Smith C, Yerasimides J, Lach J (2008) Sports hernias: a systematic literature review. *Br J Sports Med* 42(12):954–964
 50. van Veen RN, de Baat P, Heijboer MP, Kazemier G, Punt BJ, Dwarkasing RS, Bonjer HJ, van Eijck CH (2007) Successful endoscopic treatment of chronic groin pain in athletes. *Surg Endosc* 21(2):189–193
 51. Paajanen H, Brinck T, Hermunen H, Airo I (2011) Laparoscopic surgery for chronic groin pain in athletes is more effective than nonoperative treatment: a randomized clinical trial with magnetic resonance imaging of 60 patients with sportsman's hernia (athletic pubalgia). *Surgery* 150(1):99–107
 52. Kluin J, den Hoed PT, van Linschoten R, IJzerman JC, van Steensel CJ (2004) Endoscopic evaluation and treatment of groin pain in the athlete. *Am J Sports Med* 32(4):944–949
 53. Schwetling R, Bärlechner E (1998) Is there an indication for general perioperative antibiotic prophylaxis in laparoscopic plastic hernia repair with implantation of alloplastic tissue? *Zentralbl Chir* 123(2):193–195
 54. Sanchez-Manuel FJ, Lozano-García J, Seco-Gil JL (2012) Antibiotic prophylaxis for hernia repair. *Cochrane Database Syst Rev* 2:CD003769
 55. Currie A, Andrew H, Tonsi A, Hurley PR, Taribagil S (2012) Lightweight versus heavyweight mesh in laparoscopic inguinal hernia repair: a meta-analysis. *Surg Endosc* 26(8):2126–2133
 56. Bringman S, Wollert S, Osterberg J, Heikkinen T (2005) Early results of a randomized multicenter trial comparing Prolene and Vyproll mesh in bilateral endoscopic extraperitoneal hernioplasty (TEP). *Surg Endosc* 19(4):536–540
 57. Langenbach MR, Schmidt J, Ubrig B, Zirngibl H (2008) Sixty-month follow-up after endoscopic inguinal hernia repair with three types of mesh: a prospective randomized trial. *Surg Endosc* 22(8):1790–1797
 58. Agarwal BB, Agarwal KA, Mahajan KC (2009) Prospective double-blind randomized controlled study comparing heavy- and lightweight polypropylene mesh in totally extraperitoneal repair of inguinal hernia: early results. *Surg Endosc* 23(2):242–247
 59. Peeters E, Spiessens C, Oyen R, De Wever L, Vanderschueren D, Penninckx F, Miserez M (2010) Laparoscopic inguinal hernia repair in men with lightweight meshes may significantly impair sperm motility: a randomized controlled trial. *Ann Surg* 252(2): 240–246
 60. Chui LB, Ng WT, Sze YS, Yuen KS, Wong YT, Kong CK (2010) Prospective, randomized, controlled trial comparing lightweight versus heavyweight mesh in chronic pain incidence after TEP repair of bilateral inguinal hernia. *Surg Endosc* 24(11):2735–2738
 61. Chowbey PK, Garg N, Sharma A, Khullar R, Soni V, Bajjal M, Mittal T (2010) Prospective randomized clinical trial comparing lightweight mesh and heavyweight polypropylene mesh in endoscopic totally extraperitoneal groin hernia repair. *Surg Endosc* 24(12):3073–3079
 62. Bittner R, Leibl BJ, Kraft B, Schwarz J (2011) One-year results of a prospective, randomised clinical trial comparing four meshes in laparoscopic inguinal hernia repair (TAPP). *Hernia* 15(5):503–510
 63. Smith AI, Royston CM, Sedman PC (1999) Stapled and non-stapled laparoscopic transabdominal preperitoneal (TAPP) inguinal hernia repair. A prospective randomized trial. *Surg Endosc* 13(8):804–806
 64. Olmi S, Scaini A, Erba L, Guaglio M, Croce E (2007) Quantification of pain in laparoscopic transabdominal preperitoneal (TAPP) inguinal hernioplasty identifies marked differences between prosthesis fixation systems. *Surgery* 142(1):40–46
 65. Fortelny RH, Petter-Puchner AH, May C, Jaksch W, Benesch T, Khakpour Z, Redl H, Glaser KS (2012) The impact of atraumatic fibrin sealant vs. staple mesh fixation in TAPP hernia repair on chronic pain and quality of life: results of a randomized controlled study. *Surg Endosc* 26(1):249–254
 66. Brügger L, Bloesch M, Ipaktchi R, Kurmann A, Candinas D, Beldi G (2012) Objective hypoesthesia and pain after transabdominal preperitoneal hernioplasty: a prospective, randomized study comparing tissue adhesive versus spiral tacks. *Surg Endosc* 26(4):1079–1085
 67. Lovisetto F, Zonta S, Rota E, Mazzilli M, Bardone M, Bottero L, Faillace G, Longoni M (2007) Use of human fibrin glue (Tissucol) versus staples for mesh fixation in laparoscopic transabdominal preperitoneal hernioplasty: a prospective, randomized study. *Ann Surg* 245(2):222–231
 68. Boldo E, Armelles A, Perez de Lucia G, Martin F, Aracil JP, Miralles JM, Martinez D, Escrig J (2008) Pain after laparoscopic bilateral hernioplasty: early results of a prospective randomized double-blind study comparing fibrin versus staples. *Surg Endosc* 22(5):1206–1209
 69. Tam KW, Liang HH, Chai CY (2010) Outcomes of staple fixation of mesh versus nonfixation in laparoscopic total extraperitoneal inguinal repair: a meta-analysis of randomized controlled trials. *World J Surg* 34(12):3065–3074
 70. Teng YJ, Pan SM, Liu YL, Yang KH, Zhang YC, Tian JH, Han JX (2011) A meta-analysis of randomized controlled trials of fixation versus nonfixation of mesh in laparoscopic total extraperitoneal inguinal hernia repair. *Surg Endosc* 25(9):2849–2858
 71. Kaul A, Hutfless S, Le H, Hamed SA, Tymitz K, Nguyen H, Marohn MR (2012) Staple versus fibrin glue fixation in laparoscopic total extraperitoneal repair of inguinal hernia: a systematic review and meta-analysis. *Surg Endosc* 26(5):1269–1278
 72. Garg P, Nair S, Shereef M, Thakur JD, Nain N, Menon GR, Ismail M (2011) Mesh fixation compared to nonfixation in total extraperitoneal inguinal hernia repair: a randomized controlled trial in a rural center in India. *Surg Endosc* 25(10):3300–3306
 73. Gersin KS, Heniford BT, Garcia-Ruiz A, Ponsky JL (1999) Missed lipoma of the spermatic cord. A pitfall of transabdominal preperitoneal laparoscopic hernia repair. *Surg Endosc* 13(6): 585–587
 74. Nasr AO, Tormey S, Walsh TN (2005) Lipoma of the cord and round ligament: an overlooked diagnosis? *Hernia* 9(3):245–247
 75. Lau H, Loong F, Yuen WK, Patil NG (2007) Management of herniated retroperitoneal adipose tissue during endoscopic extraperitoneal inguinal hernioplasty. *Surg Endosc* 21(9):1612–1616
 76. Carilli S, Alper A, Emre A (2004) Inguinal cord lipomas. *Hernia* 8(3):252–254
 77. Langeveld HR, van't Riet M, Weidema WF, Stassen LP, Steyerberg EW, Lange J, Bonjer HJ, Jeekel J (2010) Total extraperitoneal inguinal hernia repair compared with Lichtenstein (the LEVEL-Trial): a randomized controlled trial. *Ann Surg* 251(5):819–824
 78. Fleming WR, Elliott TB, Jones RM, Hardy KJ (2001) Randomized clinical trial comparing totally extraperitoneal inguinal hernia repair with the Shouldice technique. *Br J Surg* 88(9): 1183–1188
 79. Schmedt CG, Sauerland S, Bittner R (2005) Comparison of endoscopic procedures vs Lichtenstein and other open mesh techniques for inguinal hernia repair: a meta-analysis of randomized controlled trials. *Surg Endosc* 19(2):188–199
 80. Bittner R, Sauerland S, Schmedt CG (2005) Comparison of endoscopic techniques vs Shouldice and other open nonmesh techniques for inguinal hernia repair: a meta-analysis of randomized controlled trials. *Surg Endosc* 19(5):605–615
 81. Eklund A, Rudberg C, Smedberg S, Enander LK, Leijonmarck CE, Osterberg J, Montgomery A (2006) Short-term results of a

- randomized clinical trial comparing Lichtenstein open repair with totally extraperitoneal laparoscopic inguinal hernia repair. *Br J Surg* 93(9):1060–1068
82. Eklund A, Rudberg C, Leijonmarck CE, Rasmussen I, Spangen L, Wickbom G, Wingren U, Montgomery A (2007) Recurrent inguinal hernia: randomized multicenter trial comparing laparoscopic and Lichtenstein repair. *Surg Endosc* 21(4):634–640
 83. Pokorny H, Klingler A, Schmid T, Fortelny R, Hollinsky C, Kawji R, Steiner E, Pernthaler H, Függer R, Scheyer M (2008) Recurrence and complications after laparoscopic versus open inguinal hernia repair: results of a prospective randomized multicenter trial. *Hernia* 12(4):385–389
 84. Wake BL, McCormack K, Fraser C, Vale L, Perez J, Grant AM (2005) Transabdominal pre-peritoneal (TAPP) vs totally extraperitoneal (TEP) laparoscopic techniques for inguinal hernia repair. *Cochrane Database Syst Rev* 1:CD004703
 85. Bektaş H, Bilsel Y, Ersöz F, Sarı S, Mutlu T, Arıkan S, Kaygusuz A (2011) Comparison of totally extraperitoneal technique and darn plication of primary inguinal hernia. *J Laparoendosc Adv Surg Tech A* 21(7):583–588
 86. Kumar S, Nixon SJ, MacIntyre IM (1999) Laparoscopic or Lichtenstein repair for recurrent inguinal hernia: one unit's experience. *J R Coll Surg Edinb* 44(5):301–302
 87. Dedemadi G, Sgourakis G, Karaliotas C, Christofides T, Koutraklis G, Karaliotas C (2006) Comparison of laparoscopic and open tension-free repair of recurrent inguinal hernias: a prospective randomized study. *Surg Endosc* 20(7):1099–1104
 88. Memon MA, Cooper NJ, Memon B, Memon MI, Abrams KR (2003) Meta-analysis of randomized clinical trials comparing open and laparoscopic inguinal hernia repair. *Br J Surg* 90(12):1479–1492
 89. Felix E, Scott S, Crafton B, Geis P, Duncan T, Sewell R, McKernan B (1998) Causes of recurrence after laparoscopic hernioplasty. A multicenter study. *Surg Endosc* 12(3):226–231
 90. Tamme C, Scheidbach H, Hampe C, Schneider C, Köckerling F (2003) Totally extraperitoneal endoscopic inguinal hernia repair (TEP). *Surg Endosc* 17(2):190–195
 91. Leibl BJ, Jäger C, Kraft B, Kraft K, Schwarz J, Ulrich M, Bittner R (2005) Laparoscopic hernia repair—TAPP or/and TEP? *Langenbecks Arch Surg* 390(2):77–82
 92. Liem MS, Halsema JA, van der Graaf Y, Schrijvers AJ, van Vroonhoven TJ (1997) Cost-effectiveness of extraperitoneal laparoscopic inguinal hernia repair: a randomized comparison with conventional herniorrhaphy. *Coala trial group. Ann Surg* 226(6):668–675
 93. Köninger J, Redecke J, Butters M (2004) Chronic pain after hernia repair: a randomized trial comparing Shouldice, Lichtenstein and TAPP. *Langenbecks Arch Surg* 389(5):361–365
 94. Singh AN, Bansal VK, Misra MC, Kumar S, Rajeshwari S, Kumar A, Sagar R, Kumar A (2012) Testicular functions, chronic groin pain, and quality of life after laparoscopic and open mesh repair of inguinal hernia: a prospective randomized controlled trial. *Surg Endosc* 26(5):1304–1317
 95. Gholghesaei M, Langeveld HR, Veldkamp R, Bonjer HJ (2005) Costs and quality of life after endoscopic repair of inguinal hernia vs open tension-free repair: a review. *Surg Endosc* 19(6):816–821
 96. Tschudi JF, Wagner M, Klaiher C, Brugger JJ, Frei E, Krähenbühl L, Inderbitzi R, Boinski J, Hsu Schmitz SF, Hüsler J (2001) Randomized controlled trial of laparoscopic transabdominal preperitoneal hernioplasty vs Shouldice repair. *Surg Endosc* 15(11):1263–1266
 97. Napier T, Olson JT, Windmiller J, Treat J (2008) A long-term follow-up of a single rural surgeon's experience with laparoscopic inguinal hernia repair. *WJM* 107(3):136–139
 98. Hallén M, Westerdahl J, Nordin P, Gunnarsson U, Sandblom G (2012) Mesh hernia repair and male infertility: a retrospective register study. *Surgery* 151(1):94–98
 99. Robertson GS, Burton PR, Haynes IG (1993) How long do patients convalesce after inguinal herniorrhaphy? Current principles and practice. *Ann R Coll Surg Engl* 75(1):30–33
 100. Shulman AG, Amid PK, Lichtenstein IL (1994) Returning to work after herniorrhaphy. *BMJ* 309(6949):216–217
 101. Ross AP (1975) Incidence of inguinal hernia recurrence. Effect of time off work after repair. *Ann R Coll Surg Engl* 57(6):326–328
 102. Bourke JB, Lear PA, Taylor M (1981) Effect of early return to work after elective repair of inguinal hernia: clinical and financial consequences at one year and three years. *Lancet* 2(8247):623–625
 103. Taylor EW, Dewar EP (1983) Early return to work after repair of a unilateral inguinal hernia. *Br J Surg* 70(10):599–600
 104. Callesen T, Klarskov B, Bech K, Kehlet H (1999) Short convalescence after inguinal herniorrhaphy with standardised recommendations: duration and reasons for delayed return to work. *Eur J Surg* 165(3):236–241
 105. Bay-Nielsen M, Thomsen H, Andersen FH, Bendix JH, Sørensen OK, Skovgaard N, Kehlet H (2004) Convalescence after inguinal herniorrhaphy. *Br J Surg* 91(3):362–367
 106. Welsh CL, Hopton D (1980) Advice about driving after herniorrhaphy. *Br Med J* 280(6223):1134–1135
 107. Wilson MS, Irving SO, Iddon J, Deans GT, Brough WA (1998) A measurement of the ability to drive after different types of inguinal hernia repair. *Surg Laparosc Endosc* 8(5):384–387
 108. Kald A, Nilsson E (1991) Quality assessment in hernia surgery. *Qual Assur Health Care* 3(3):205–210
 109. Haapaniemi S, Nilsson E (2002) Recurrence and pain three years after groin hernia repair. Validation of postal questionnaire and selective physical examination as a method of follow-up. *Eur J Surg* 168(1):22–28
 110. López-Cano M, Vilallonga R, Sánchez JL, Hermosilla E, Armengol M (2007) Short postal questionnaire and selective clinical examination combined with repeat mailing and telephone reminders as a method of follow-up in hernia surgery. *Hernia* 11(5):397–402
 111. Brazier JE, Harper R, Jones NM, O'Cathain A, Thomas KJ, Usherwood T, Westlake L (1992) Validating the SF-36 health survey questionnaire: new outcome measure for primary care. *BMJ* 305(6846):160–164
 112. Heniford BT, Walters AL, Lincourt AE, Novitsky YW, Hope WW, Kercher KW (2008) Comparison of generic versus specific quality-of-life scales for mesh hernia repairs. *J Am Coll Surg* 206(4):638–644
 113. Muysoms F, Campanelli G, Champault GG, DeBeaux AC, Dietz UA, Jeekel J, Klinge U, Köckerling F, Mandala V, Montgomery A, Morales Conde S, Puppe F, Simmermacher RK, Śmietański M, Miserez M (2012) EuraHS: the development of an international online platform for registration and outcome measurement of ventral abdominal wall hernia repair. *Hernia* 16(3):239–250
 114. Loos MJ, Houterman S, Scheltinga MR, Roumen RM (2008) Evaluating postherniorrhaphy groin pain: visual analogue or verbal rating scale? *Hernia* 12(2):147–151
 115. Fränneby U, Gunnarsson U, Andersson M, Heuman R, Nordin P, Nyrén O, Sandblom G (2008) Validation of an inguinal pain questionnaire for assessment of chronic pain after groin hernia repair. *Br J Surg* 95(4):488–493
 116. Lamb AD, Robson AJ, Nixon SJ (2006) Recurrence after totally extraperitoneal laparoscopic repair: implications for operative technique and surgical training. *Surgeon* 4(5):299–307
 117. Lovisetto F, Zonta S, Rota E, Bottero L, Faillace G, Turra G, Fantini A, Longoni M (2007) Laparoscopic transabdominal

- preperitoneal (TAPP) hernia repair: surgical phases and complications. *Surg Endosc* 21(4):646–652
118. Choi YY, Kim Z, Hur KY (2012) Learning curve for laparoscopic totally extraperitoneal repair of inguinal hernia. *Can J Surg* 55(1):33–36
 119. Liem MS, van Steensel CJ, Boelhouwer RU, Weidema WF, Clevers GJ, Meijer WS, Vente JP, de Vries LS, van Vroonhoven TJ (1996) The learning curve for totally extraperitoneal laparoscopic inguinal hernia repair. *Am J Surg* 171(2):281–285
 120. Feliu-Palà X, Martín-Gómez M, Morales-Conde S, Fernández-Sallent E (2001) The impact of the surgeon's experience on the results of laparoscopic hernia repair. *Surg Endosc* 15(12):1467–1470
 121. Deysine M (2001) Hernia clinic in a teaching institution: creation and development. *Hernia* 5(2):65–69
 122. Zendejas B, Cook DA, Bingener J, Huebner M, Dunn WF, Sarr MG, Farley DR (2011) Simulation-based mastery learning improves patient outcomes in laparoscopic inguinal hernia repair: a randomized controlled trial. *Ann Surg* 254(3):502–509
 123. Kingsnorth AN, Bowley DM, Porter C (2003) A prospective study of 1000 hernias: results of the Plymouth Hernia Service. *Ann R Coll Surg Engl* 85(1):18–22
 124. Heikkinen T, Haukipuro K, Leppälä J, Hulkko A (1997) Total costs of laparoscopic and Lichtenstein inguinal hernia repairs: a randomized prospective study. *Surg Laparosc Endosc* 7(1):1–5
 125. Wellwood J, Sculpher MJ, Stoker D, Nicholls GJ, Geddes C, Whitehead A, Singh R, Spiegelhalter D (1998) Randomised controlled trial of laparoscopic versus open mesh repair for inguinal hernia: outcome and cost. *BMJ* 317(7151):103–110
 126. Tanhiphat C, Tanprayoon T, Sangsubhan C, Chatamra K (1998) Laparoscopic vs open inguinal hernia repair. A randomized, controlled trial. *Surg Endosc* 12(6):846–851
 127. Paganini AM, Lezoche E, Carle F, Carlei F, Favretti F, Feliciotti F, Gesuita R, Guerrieri M, Lomanto D, Nardovino M, Panti M, Ribichini P, Sarli L, Sottili M, Tamburini A, Taschieri A (1998) A randomized, controlled, clinical study of laparoscopic vs open tension-free inguinal hernia repair. *Surg Endosc* 12(7):979–986
 128. Heikkinen TJ, Haukipuro K, Koivukangas P, Hulkko A (1998) A prospective randomized outcome and cost comparison of totally extraperitoneal endoscopic hernioplasty versus Lichtenstein hernia operation among employed patients. *Surg Laparosc Endosc* 8(5):338–344
 129. Medical Research Council Laparoscopic Groin Hernia Trial Group (2001) Cost-utility analysis of open versus laparoscopic groin hernia repair: results from a multicentre randomized clinical trial. *Br J Surg* 88(5):653–661
 130. Papachristou EA, Mitselou MF, Finokaliotis ND (2002) Surgical outcome and hospital cost analyses of laparoscopic and open tension-free hernia repair. *Hernia* 6(2):68–72
 131. Schneider BE, Castillo JM, Villegas L, Scott DJ, Jones DB (2003) Laparoscopic totally extraperitoneal versus Lichtenstein herniorrhaphy: cost comparison at teaching hospitals. *Surg Laparosc Endosc Percutan Tech* 13(4):261–267
 132. Khajanchee YS, Kenyon TA, Hansen PD, Swanström LL (2004) Economic evaluation of laparoscopic and open inguinal herniorrhaphies: the effect of cost-containment measures and internal hospital policy decisions on costs and charges. *Hernia* 8(3):196–202
 133. Anadol ZA, Ersoy E, Taneri F, Tekin E (2004) Outcome and cost comparison of laparoscopic transabdominal preperitoneal hernia repair versus open Lichtenstein technique. *J Laparoendosc Adv Surg Tech A* 14(3):159–163
 134. Hynes DM, Stroupe KT, Luo P, Giobbie-Hurder A, Reda D, Kraft M, Itani K, Fitzgibbons R, Jonasson O, Neumayer L (2006) Cost effectiveness of laparoscopic versus open mesh hernia operation: results of a department of Veterans affairs randomized clinical trial. *J Am Coll Surg* 203(4):447–457
 135. Jacobs VR, Morrison JE (2008) Comparison of institutional costs for laparoscopic preperitoneal inguinal hernia versus open repair and its reimbursement in an ambulatory surgery center. *Surg Laparosc Endosc Percutan Tech* 18(1):70–74
 136. Butler RE, Burke R, Schneider JJ, Brar H, Lucha PA (2007) The economic impact of laparoscopic inguinal hernia repair: results of a double-blinded, prospective, randomized trial. *Surg Endosc* 21(3):387–390
 137. Stylopoulos N, Gazelle GS, Rattner DW (2003) A cost-utility analysis of treatment options for inguinal hernia in 1,513,008 adult patients. *Surg Endosc* 17(2):180–189
 138. Vale L, Ludbrook A, Grant A (2003) Assessing the costs and consequences of laparoscopic vs. open methods of groin hernia repair: a systematic review. *Surg Endosc* 17(6):844–849
 139. Vale L, Grant A, McCormack K, Scott NW, EU Hernia Trialists Collaboration (2004) Cost-effectiveness of alternative methods of surgical repair of inguinal hernia. *Int J Technol Assess Health Care* 20(2):192–200
 140. McCormack K, Wake BL, Fraser C, Vale L, Perez J, Grant A (2005) Transabdominal pre-peritoneal (TAPP) versus totally extraperitoneal (TEP) laparoscopic techniques for inguinal hernia repair: a systematic review. *Hernia* 9(2):109–114
 141. Kuhry E, van Veen RN, Langeveld HR, Steyerberg EW, Jeekel J, Bonjer HJ (2007) Open or endoscopic total extraperitoneal inguinal hernia repair? A systematic review. *Surg Endosc* 21(2):161–166